

Detection of Infiltrate on Infant Chest X-Ray

Jufriadif Na`am^{*1}, Johan Harlan², Gunadi Widi Nercahyo³, Syafri Arlis⁴, Sahari⁵,
Mardison⁶, Larissa Navia Rani⁷

^{1,3,4,5,6,7}Computer Science Faculty, Universitas Putra Indonesia YPTK, Padang, 25221, Indonesia

²Computer Science Faculty, Universitas Gunadarma, Jakarta, 16424, Indonesia

*Corresponding author, e-mail: jufriadifnaam@gmail.com¹, harlan_johan@hotmail.com²,
gunadiwidi@yahoo.co.id³, syafri_arlis@upiyptk.ac.id⁴, sahari@upiyptk.ac.id⁵; md_slk18@yahoo.com⁶;
larissanr87@gmail.com⁷

Abstract

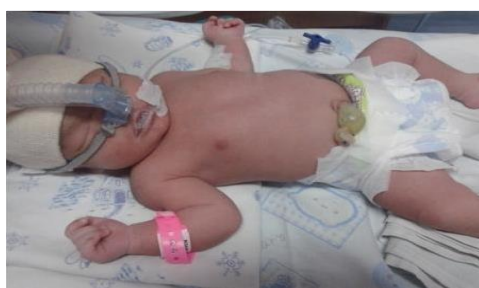Currently, Chest X-ray is still widely used around the world for disease examination. This is due to its low cost, low radiation and a lot of disease information. The commonly detected disease using chest x-rays is lung disease. The characteristic of this disease is infiltrate. However, the accuracy of Chest X-ray observations is still low. Therefore, this research offers a method to perform Chest X-ray image processing in clarifying the information contained therein. This research used Chest X-ray of infant patients who treated at Central Public Hospital (RSUP) Dr. M. Djamil Padang. The total of the images tested were 17 images. In these images, there were some suspected infiltrates after being analyzed by doctors. Software used was Matlab which is conducted by applying image processing method. The method used consisted of 4 parts, that was Cropping, Filtering, Detecting Edge, and Sharpening Edge. The results of the research showed that the method could clarify edge detection of the objects contained in the image, so that the infiltrate could be more easily recognized. With this easiness, it will help the doctor to remove doubts for infiltrate observations in the Infant's lungs.

Keywords: medical image; infiltrate; chest x-ray; infant; sharpen

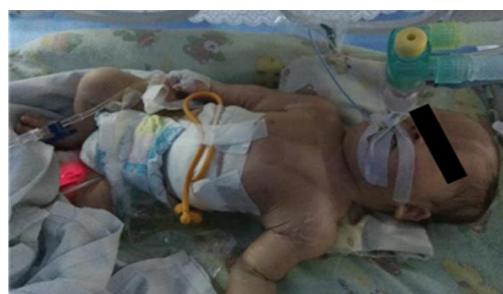Copyright © 2017 Universitas Ahmad Dahlan. All rights reserved.

1. Introduction

One of medical image is chest x-ray. Chest x-rays offer simplicity, low cost, low radiation, lots of information, and worldwide availability.. The purpose of the chest x-ray use was to prove the doctor's perception in identifying lung disease [1]. Characteristics of patient infants who suffer from lung disease were installed with respiratory aids. Figure 1 shows, infants who were suspected from lung diseases, in which respiratory aids were installed for both of them. Figure 1(a) is the CPAP in nose and Figure 1(b) is the Ventilator in mouth. The existence of infiltrate in the lungs indicates the presence of disease in the patient's lungs. Infiltrate is an abnormal pulmonary feature that can be seen at Chest X-Ray image [2]. There are white patches in the image [3]. These white patches can be liquid or dense. The types of diseases that can cause infiltrates are tuberculosis or pulmonary [4].



(a)



(b)

Figure 1. Infant Having Lung Disease With Respiratory Aids at RSUP Dr. M. Jamil Padang
(a) Continuous Positive Airway Pressure (CPAP), (b) Ventilator

Infiltrate on radiographic images can be only analyzed by experts such as radiologist or doctors. They should do a careful observation, but the accuracy is still low [5]. This is due to the fact that it is required image processing to clarify the information contained in the medical image. The purpose of the image processing is to clarify the object and to facilitate observing objects contained in medical images [6-12]. Some researches on Chest X-Ray image processing by using certain method can be seen in Table 1.

Table 1. Previous Research on Chest X-Ray

Reserchers	Methods	Object	Result
Dellios, Teichgraeber, Chelaru, Malich and Papageorgiou	Computer-Aided Detection (CAD)	Pulmonary Nodules	Not qualify .[13]
Gerrand, Williams, Lunga, Pantanowitz, Madhi and Nasreen Mahomed	Convolutional Neural Networks (CNN)	Tuberculosis and Pneumonia	Promising. [14]
Ture and Kayikcioglu	Contrast limited adaptive histogram equalization (CLAHE)	Lung Cancer	A very satisfactory. [15]
Wilson, Aidoo and Acquah	Support Vector Machine (SVM)	Lung nodules	High image sensitivity. [16]
Santony and Na'am	Math-Morphology	Infiltrate	Clearly. [17]
Khobragade, Tiwari, Patil and Narke	Artificial Neural Network	Tuberculosis (TB)	Sufficient. [18]
Ahmad, Zaki and Fauzi	Fuzzy C-Means (FCM)	Lung	Good performance, strong, and fast in segmentation. [19]
Alavijeh and Mahdavi-Nasab	Discrete Wavelet Transform (DWT)	Chest tissue	Fixed the image contrast really well. [20]
Zhu, Luo, Li, Chen, Yang, Xu, Wu, Chen and Zhang	Support Vector Machine (SVM)	Pneumoconiosis	Good potential. [21]
Orban and Horvath	Support Vector Machine (SVM)	Lung Cancer	Accuracy = 60,2%. [22]

However, there is not much research yet about infiltrate on chest x-ray image of Infants. So in this research, the author did image processing on Chest X-Ray images in infants. The objective of the research was to detect the infiltrates contained in the image, therefore it can assist the doctors in analyzing the lung disease in the infant.

2. Research Method

The images tested in this research were the images of Chest X-ray of the patients who were paired with respiratory aids at RSUP M. Djamil Padang. The images were taken using Computed Radiography. The Images had been saved in digital form with PNG (Portable Network Graphics) extensions.

The total of patient images tested was 17 (seventeen) infants. Each patient had one Chest X-ray image. These images were first analyzed by a doctor. The result showed that there was suspect infiltrate. The data presented in this paper were 2 (two) images as representative of all the images processed in this research. Both images were Chest X-ray images of infant patients as presented in Figure 1. The software used for processing the images was Matlab with the stages of process can be seen in Figure 2.

Stages of process in this research consist of 5 (five) parts. The 5 parts of the process are grouped into 2 main parts, they are the preprocessing and enhancement sections. The preprocessing section is used to remove areas in the image other than the chest and to eliminate noise. The enhancement section is used to improve image quality. Each process produces an image that will use in the next process. The end of the process will produce an image that further clarifies the objects contained in the image.

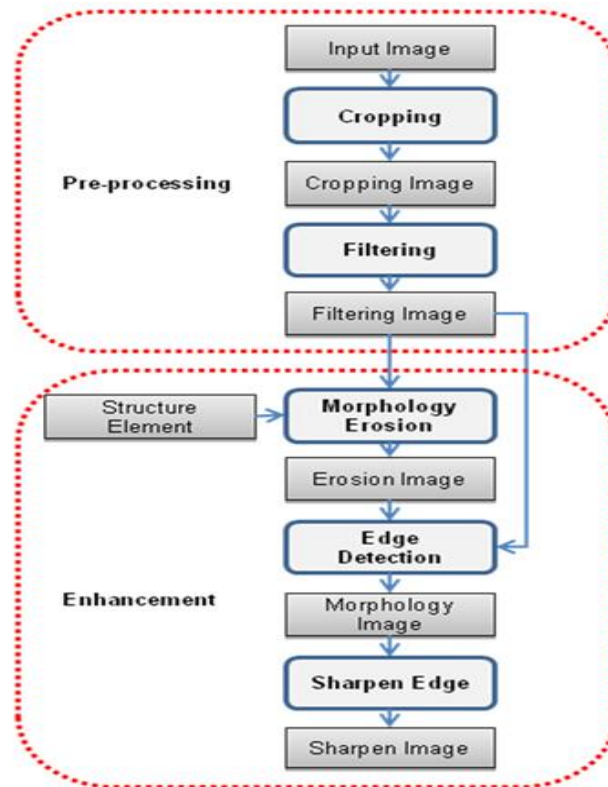
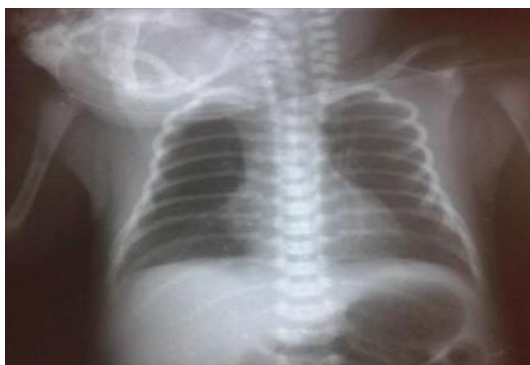

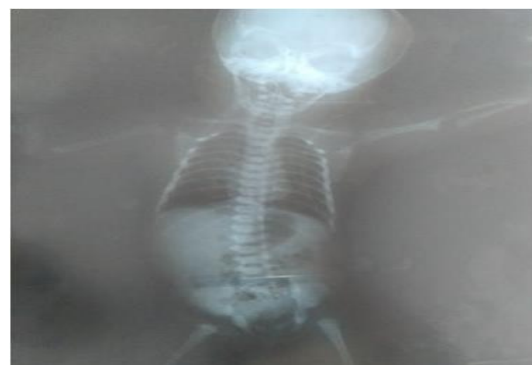Figure 2. Stages of Process

3. Results and Analysis

Based on the stages of the process in Figure 2 above, then the tested Chest X-ray images of infant patient were as the input image. The test image presented in this paper was the Chest X-ray image of patients using respiratory aids, as shown in Figure 3.



(a)



(b)

Figure 3. . Chest X-Ray of 1st Patient (a) and 2nd Patient (b)

Figure 3 shows Chest X-rays of patients in Figure 1. The 1st figure (3 a) is a Chest X-ray of an infant paired with a CPAP device and the 2nd figure (3 b) is a Chest X-ray of an infant paired with a Ventilator device. Those images still have some areas that is not required in

detecting infiltrate and the quality is still low. For that, It will do the next process in order to infiltrate in the image is more easily recognizable.

3.1. Cropping

The first process is cropping. This process aims to cut off unneeded areas in the next process to get the infiltrate area. The cropping technique takes the input image area from the top left coordinate point to the bottom right coordinate point manually [23]. Illustration of the cropping process can be seen in Figure 4

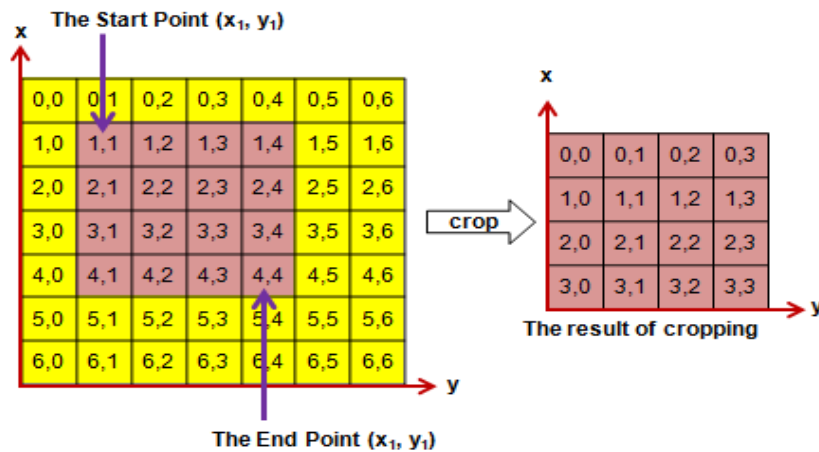
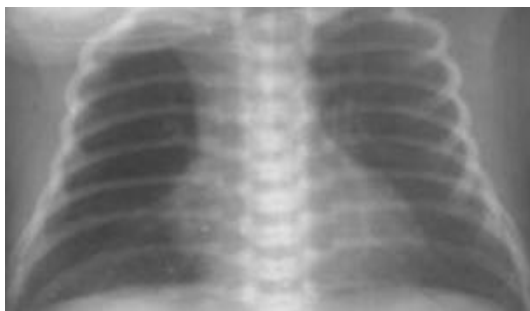
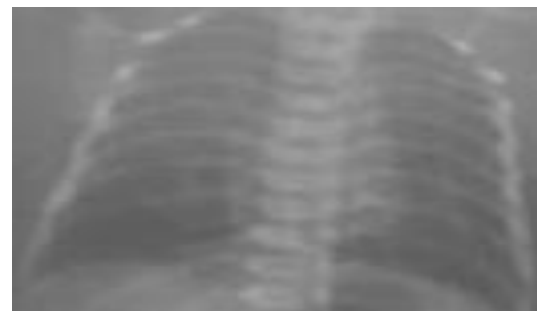


Figure 4. Cropping Process

Result of cropping images in Figure 5 showed that unnecessary area for the next process had been removed. However, the images still had a lot of noise. The noise is a pixel that interferes with image quality in the form of black or white spots which are scattered randomly. To eliminate this noise, then filtering process will be conducted.



(a)



(b)

Figure 5. Result of cropping image of 1st patient (a) and 2nd patient (b)

3.2. Filtering

The next process after being cropped is removing the noise on the result of cropping images. The noise is the pixel value that interferes with image quality. The value of the noise pixel is either too low or too high in which the values were randomly distributed. The noise could be eliminated by doing filter process. Filtering is an activity of avoiding noise in the process of adjusting the pixel value in the level of the histogram value [24],[25]. The filter method is Gaussian Filter with the following equation:

$$G(x, y) = \frac{1}{2\pi\sigma^2} \exp(-(x^2 + y^2)/2\sigma^2) \tag{1}$$

where:

- a. G: result of Gaussian Filter process
- b. σ : standard distribution deviation function, where the center of the distribution lies on x axis; $x=0$ (mean=0).

The results of filtering can be seen in Figure 6. Value of pixels was too high and too low at random that was adjusted.

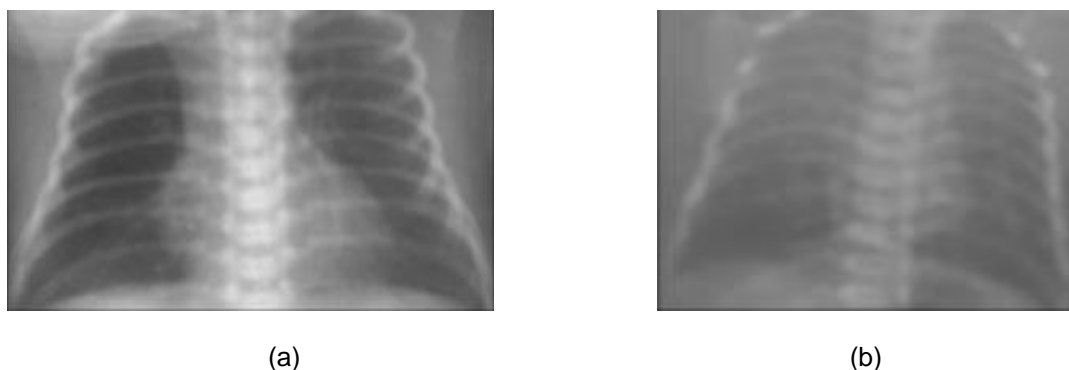


Figure 6. Result of filtering Image of 1st patient (a) and 2nd patient (b)

A part of pixel value can be seen in Figure 7. In Figure 7 (a), it appeared that the pixel value 99 at the beginning of the arrow was very striking in its value difference from its neighboring pixels. Then in Figure 7 (b), it was adjusted to all the neighboring pixel values, so it was not flashy.

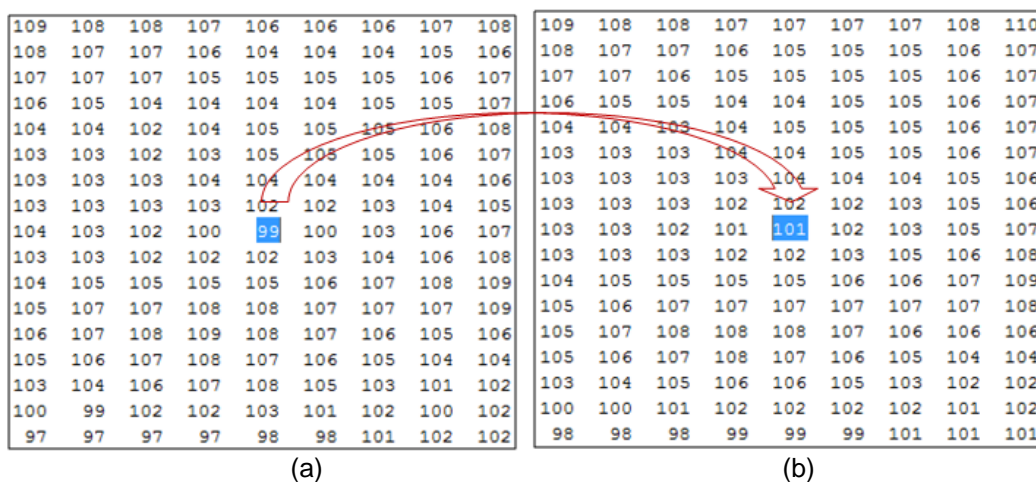


Figure 7. Value of Pixel before Filtering (a) and After Filtering (b)

3.3. Morphology Erosion

The result of filtering image was still not clearly visible for edge detection of the objects contained in the Chest X-ray. To form the edge detection, the first process conducted was morphology erosion. The morphology erosion is minimizing the total of pixels that make up the

edge detection of an object. The pixels that make up edge detection are high-value pixel. The form of the equation is as follows:

$$G \ominus B = \{z \mid (B)_z \subseteq A\} \quad (2)$$

where:

- $G \ominus B$: result of erosion process
- z : a shift mapping
- B : matrix of structure element.

Structure element is a two dimensional matrix as a map to the operated image. The value of each element is between 1 or 0. In this processing, structure element was 2x2 matrix. The value of each element was 1, as shows in Figure 8.

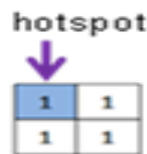

Figure 8. Structure Element

Where:

- Element on row 1 and column 1 as hotspot.

The purpose of using the structure element in Figure 8 was that the image of being processed which did not exist would eliminate pixels and the size of the object remains the same as the filter image. The result of Morphology Erosion is not displayed and stored permanently, but it is only for the next process.

3.4. Edge Detection

Edge detection is the process of forming the edges of an object. This stage reduces the image of the filter with the image of morphology erosion result. The equation for the edge detection is as follows:

$$E = G - (G \ominus B) \quad (3)$$

The results of the edge detection process can be seen in Figure 9.

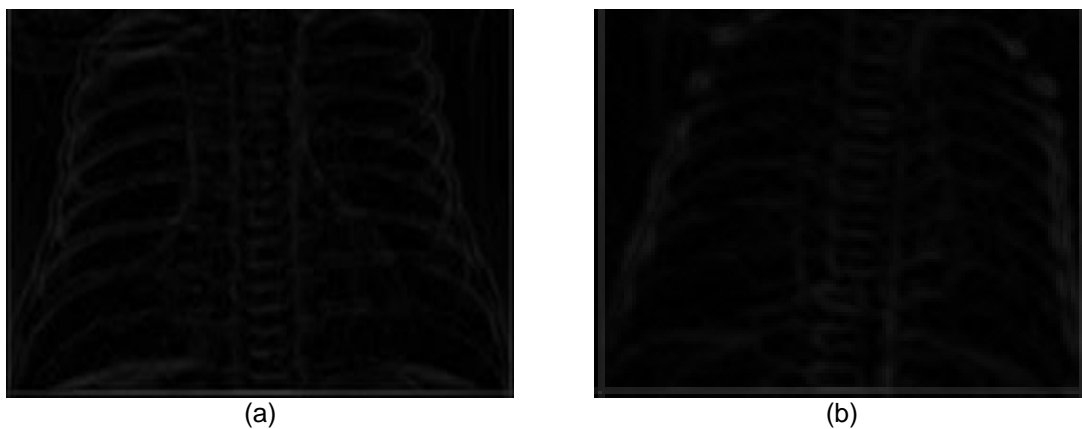


Figure 9. Result of Edge Detection image of 1st patient (a) and 2nd patient (b)

In the image of edge detection result above it had formed edge boundary of the object in the image. The edge pixels value were still low. Figure 10 shows a distinct group of striking pixel value (red circles) with other pixel value. The values of the circled pixels were the edge detection values that had been formed from the edge detection process. The difference of the values was not significantly, then following process was Sharpen Edge.

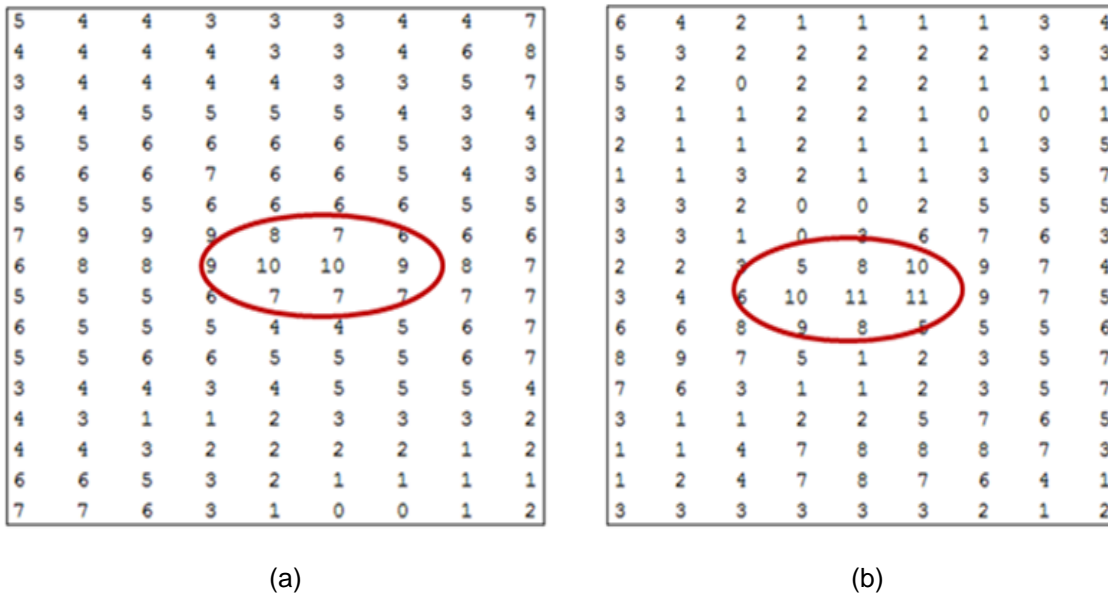


Figure 10. The Pixel Value of Edge Detection Results for 1st Patient (a) and 2nd Patient (b)

3.4. Sharpen Edge

The sharpen edge process was aimed to sharp the edge of every object in the image. The edge pixel value want to increase or higher than the other pixels. The form of the equation is as follows:

$$S_{(x, y)} = \text{bitdepth} * E_{(x, y)} \mid E(x, y) > T \tag{4}$$

And T is minimum Multi Threshold and its equation is as follows:

$$T = \begin{cases} 1, E < q \\ \vdots \\ \text{bitdepth}, E \geq q \end{cases} \tag{5}$$

Where:

- a. bitdepth: bit depth value
- b. q with $0 < q \leq E_{\text{max}}$.

In Figure 11, it had been seen that the edge detection of the objects contained in the image was more clearly, therefore, the objects were easier to recognize. The clear edge detection had increased the pixel value difference compared to the pixel value of which without edge detection. The clarity of the edge detection also further clarified bone and infiltrate objects. Object identified as an infiltrate was the object that existed between the bones of the chest. The infiltrate object is shown by arrows in Figure 11. The infiltrate located behind the breastbone could not be observed in this research because the bone pixel value was equal to or more than the pixel value of the infiltrate.

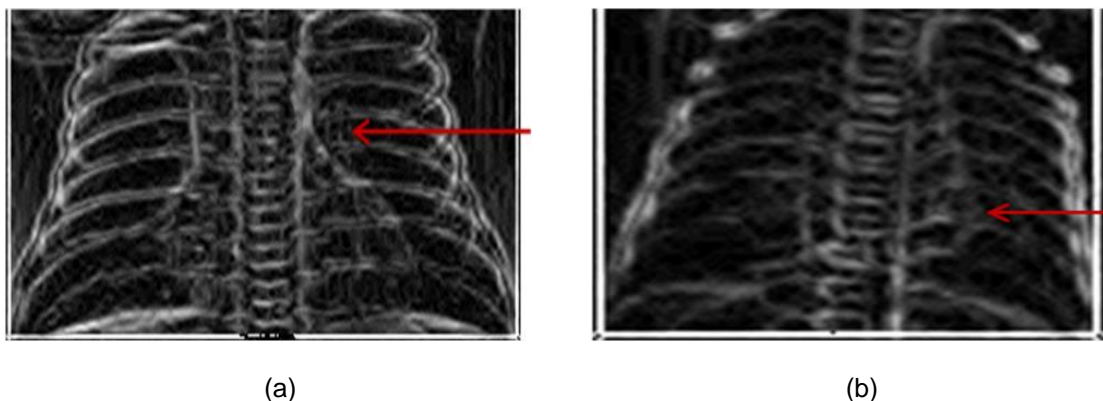


Figure 11. Result of Sharpen Edge of 1st Patient (a) and 2nd Patient (b)

4. Conclusion

Based on the stages of the process of medical image chest x-ray above it could be produced a clearer image. The results of processing image presented clearer edge detection of the object, so that the information contained in the image was more easily recognizable. The clearly identifiable objects were the infiltrate and the breastbone. The clarity of the edge detection of the object would help doctors to overcome the doubt in identifying infiltrate on infant chest x-ray.

References

- [1] Coche EE. Chest Radiography Today and Its Remaining Indications. In: Baert AL, Reiser MF, Hricak H, Knauth. Editors. *Comparative Interpretation of CT and Standard Radiography of the Chest*, Berlin: Springer, 2011: 3-26.
- [2] Patterson HS, Sponaugle DN. Is infiltrate a useful term in the interpretation of chest radiographs? Physician survey results. *Radiology*. 2005; 235(1): 5-8.
- [3] Proschek P, Vogl TJ. Chest and Mediastinum. In: Vogl TJ, Reith W, Rummeny EJ. Editors. *Diagnostic and Interventional Radiology*. Berlin: Springer. 2016: 479-590.
- [4] Clement A, Nathan N, Epaud R, Fauroux B, Corvol H. Interstitial lung diseases in children. *Orphanet Journal of Rare Diseases*. 2010; 5(22): 1-24.
- [5] Moncada DC, Rueda ZV, Macías A, Suárez T, Ortega H, Vélez LA. Reading and interpretation of chest X-ray in adults with community-acquired pneumonia. *Braz J Infect Dis*, 2011; 15(6): 540-546.
- [6] Madenda S. *Pengolahan Citra & Video Digital*. Jakarta: Erlangga, 2015: 16.
- [7] Sumijan, Madenda S, Harlan J, Wibowo EP. Hybrids Otsu method, Feature region and Mathematical Morphology for Calculating Volume Hemorrhage Brain on CT-Scan Image and 3D Reconstruction. *TELKOMNIKA Telecommunication, Computing, Electronics and Control*. 2017; 15(1): 283-291.
- [8] Na`am J. Accuracy of Panoramic Dental X-Ray Imaging in Detection of Proximal Caries with Multiple Morphological Gradient (mMG) Method. *International Journal on Informatics Visualization*. 2017; 1(1): 5-11.
- [9] Na`am J, Harlan J, Madenda S, Wibowo EP. Identification of the Proximal Caries of Dental X-Ray Image with Multiple Morphology Gradient Method. *International Journal on Advanced Science, Engineering and Information Technology*, 2016; 6(3): 343-346.
- [10] Na`am J, Harlan J, Madenda S, Wibowo EP. The Algorithm of Image Edge Detection on Panoramic Dental X-Ray Using Multiple Morphological Gradient (mMG) Method. *International Journal on Advanced Scienc, Engineering and Information Technology*. 2016; 6(6): 2012-2018.
- [11] Na`am J. *Edge Detection on Objects of Medical Image with Enhancement multiple Morphological Gradient (EmMG) Method*. Proc. EECSI 2017. Yogyakarta. Indonesia, 19-21 September 2017: pp. 61-67.
- [12] Na`am J, Harlan J, Madenda S, Wibowo EP. Image Processing of Panoramic Dental X-Ray for Identifying Proximal Caries. *TELKOMNIKA Telecommunication, Computing, Electronics and Control*, 2017; 15(2): 702-708.
- [13] Dellios N, Teichgraeber U, Chelaru R, Malich A, Papageorgiou IE. Computer-aided Detection Fidelity of Pulmonary Nodules in Chest Radiograph. *J Clin Imaging Sci*. 2017; 7(8): 1-8.

- [14] Gerrand J, Williams Q, Lunga D, Pantanowitz A, Madhi S, Mahomed N. *Paediatric Frontal Chest Radiograph Screening with Fine-Tuned Convolutional Neural Networks*, Medical Image Understanding and Analysis: 21st Annual Conference. United Kingdom. 2017: 856-868.
- [15] Ture H, Kayikcioglu T. *Detection and Segmentation of Nodules in Chest Radiographs Based on Lifetime Approach*, Proceedings of the International Conference on Medical and Biological Engineering, First Edition. Sarajevo, Bosnia and Herzegovina. 2017: 549-557.
- [16] Wilson M, Aidoo AY, Acquah CH. Chest Radiograph Image Enhancement: A Total Variation Approach, *International Journal of Computer Applications*, 2017; 163(7): 1-6.
- [17] Santony J, Na'am J. Infiltrate Object Extraction in X-ray Image by using Math-Morphology Method and Feature Region Analysis. *International Journal on Advanced Science, Engineering and Information Technology*. 2016; 6(2): 239-244.
- [18] Khobragade S, Tiwari A, Patil CY, Narke V. *Automatic Detection of Major Lung Diseases using Chest Radiographs and Classification by Feed-Forward Artificial Neural Network*. 1st IEEE International Conference on Power Electronics Intelligent Control and Energy Systems (ICPEICES-2016). Delhi. 2016: 1-5.
- [19] Ahmad WSHMW, Zaki WMDW, Fauzi MZA. Lung Segmentation on Standard and Mobile Chest Radiographs using Oriented Gaussian Derivatives Filter. *BioMedical Engineering OnLine*, 2015; 14(20): 1-26.
- [20] Alavijeh FS, Mahdavi-Nasab H. Multi-scale Morphological Image Enhancement of Chest Radiographs by a Hybrid Scheme. *Journal of Medical Signals & Sensors*. 2015; 5(1): 59-68.
- [21] Zhu B, Luo W, Li B, Chen B, Yang Q, Xu Y, Wu X, Chen H, Zhang K. The Development and Evaluation of a Computerized Diagnosis Scheme for Pneumoconiosis on Digital Chest Radiographs. *BioMedical Engineering OnLine*, 2014; 13(141): 1-14.
- [22] Orban G, Horvath G. Algorithm Fusion to Improve Detection of Lung Cancer on Chest Radiographs. *International Journal of Intelligent Computing and Cybernetics*. 2012; 5(1): 111-144.
- [23] Yuhandri, Madenda S, Wibowo EP, Karmilasari. Object Feature Extraction of Songket Image Using Chain Code Algorithm. *International Journal on Advanced Science, Engineering and Information Technology*, 2017; 7(1): 235-241.
- [24] Susetianingtias DT, Madenda S, Rahayu DA, Rodiah. Retinal Microaneurysm Detection using Maximally Stable External Region Algorithm. *International Journal on Advanced Science, Engineering and Information Technology*, 2016; 6(5): 644-648.
- [25] Cui D, Xia K, Hou J, Ali A. Image De-noising on Strip Steel Surface Defect Using Improved Compressive Sensing Algorithm. *TELKOMNIKA Telecommunication, Computing, Electronics and Control*, 2017; 15(1): 540-548.