

Image Processing of Panoramic Dental X-Ray for Identifying Proximal Caries

Jufriadif Na`am^{*1}, Johan Harlan², Sarifuddin Madenda³, Eri Prasetyo Wibowo⁴

¹Faculty of Computer Science, Universitas Putra Indonesia YPTK Padang, 25221, Indonesia

^{2,3,4}Faculty of Computer Science, Gunadarma University, Jakarta, 16424, Indonesia

Corresponding author, e-mail: jufriadifnaam@gmail.com^{*1}, harlan_johan@hotmail.com², sarif@staff.gunadarma.ac.id³, prasetyo@u-bourgogne.fr⁴

Abstract

This study aims to facilitate the identification of proximal caries in the Panoramic Dental X-Ray image. Twenty-seven X-Ray images of proximal caries were elaborated. The images in digital form were processed using Matlab and Multiple Morphological Gradients. The process produced sharper images and clarifies the edges of the objects in the images. This makes the characteristics of the proximal caries and the caries severity can be identified precisely.

Keywords: dental x-ray, multiple morphological gradient (mMG), proximal caries, level of severity

Copyright © 2017 Universitas Ahmad Dahlan. All rights reserved.

1. Introduction

Proximal caries is the caries found on the surface of the tooth facing the adjacent tooth surface in the dental arches. The most difficult caries to detect is proximal caries [1]. Proximal caries is the most difficult one to be detected visually in clinical examination [2, 3]. Radiograph called Dental X-Ray [4-6] is needed to detect this caries.

Dental X-Ray is an image of dental radiographs along with bones and soft tissues in the vicinity. X-ray image can show cavities (caries), hidden teeth and bones that can not be seen in visual inspection. Dental X-Ray images used to detect dental caries consists of:

- a. Bitewing X-ray, showing the back of the upper and lower teeth and how the teeth contact to each other in a single view.
- b. Periapical X-Ray, showing the whole picture of the tooth (covering several teeth from crown to root tip) to the surrounding jaw bone.
- c. Panoramic X-Ray, shows a view of the entire teeth, upper and lower jaw and the sinuses, the nose and the jaw joints.

Some previous studies to identify proximal caries using radiographic images can be seen in Table 1.

It can be concluded from the previous studies (Table 1) that the identification of caries proximal in Panoramic Dental X-Ray images are less favorable than that of Bitewing Dental X-Ray. Identification of proximal caries using Dental Panoramic X-Ray lowest precision was compared with both other Dental X-Ray [16]. This research is aimed to improve the quality of image processing in identifying proximal caries in Dental Panoramic X-Ray images. The process of analysis of such images is important in order to improve quantify medical imaging systems [17, 18]. It requires image processing that could generate sharper and clearer images or improve the quality of information contained in the image so that it can be visually interpreted better [19]. The image processing are very helpful in identifying objects contained in the panoramic image, especially in detecting cavities [20]. Therefore, automatic feature detection can assist doctor in processing the image in analyzing disease [21, 22].

Table 1. Some Studies on Identification of Proximal Caries in Dental X-Ray Images

Author	Type of Dental X-Ray	Result
Akarslan et al (2008)	20 images (Bitewing, Periapical, Panoramic)	Bitewing has the highest accuracy[7]
Kamburoglu et al (2012)	80 images (Intraoral Bitewing, Extraoral Bitewing (Panoramic))	Intraoral Bitewing has better accuracy[8]
Zarch et al (2013)	60 images (Bitewing, Panoramic)	Bitewing has the best accuracy[9]
Abdinian et al (2015)	100 images (Bitewing, Panoramic)	Bitewing has better accuracy[10]
Sabarinathan et al (2015)	Panoramic Dental X-Ray	A panoramic X-ray is not good for detecting tooth decay[11]
Tafakhori et al (2016)	30 patients (both Bitewing and Panoramic)	Panoramic can be a proper substitute for Bitewing[12]
Terry et al (2016)	489 images (Bitewing, Panoramic)	No significant difference[13]
Valizadeh et al (2016)	42 digital radiographic images	The enhancement options of zooming, colorization, and contrast conversion did not significantly influence the diagnostic accuracy of digital images in enamel caries[14].
Mohtavipour et al (2016)	50 patients (both Bitewing and Panoramic)	no significant difference (0.001)[15]

2. Research Method

Technological developments of radiographic (Computed Radiography) is now able to convert the analogue system product into digital form so that the images of Dental Panoramic X-Ray can be stored in soft copy in the form of files *.jpg, *.png, or *.bmp format. This file can be used through image processing to develop a system to detect proximal caries using Matlab software. To build this system it is necessary to conduct a study comprising the steps of implementation shown in Figure 1. This study consisted of six stages. One of the steps is the original contribution of this study.

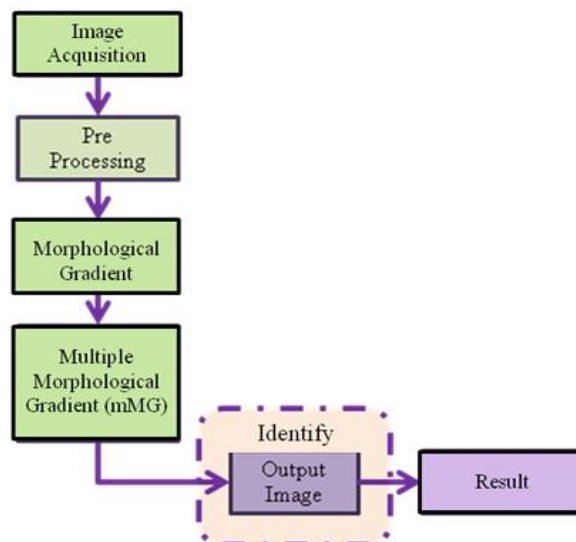


Figure 1. Stages of Research

3. Results and Analysis

This study consists of six stages of processes implemented in MatLab program and one step of manual identification analysis. The last one is the significant contribution of this study.

3.1. Image Acquisition

The image acquisition to be used as input data were panoramic dental X-ray images in the *.png format. All images used is in the form of grayscale panoramic dental X-ray, in a

standard size of 2776 × 1330 pixel. Twenty-seven images containing proximal caries were identified in this study. All images have been examined by the dentists of Semen Padang Hospital, Indonesia to detect proximal caries and its severity. The position number of teeth can be seen in Figure 2.

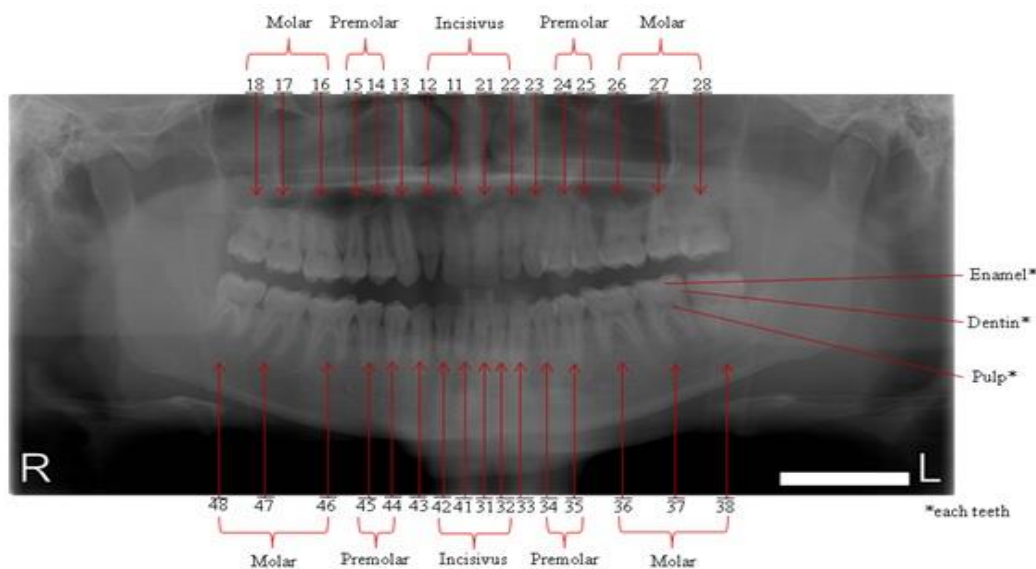


Figure 2. Position Number and Layer of Teeth

In this discussion, only three of the results of image processing of proximal caries are displayed. Each image has different characteristics, in terms of: (1) Position of caries (left or right side), (2) The number of teeth, (3) Level of severity.

Figure 3 below shows three images to be processed:

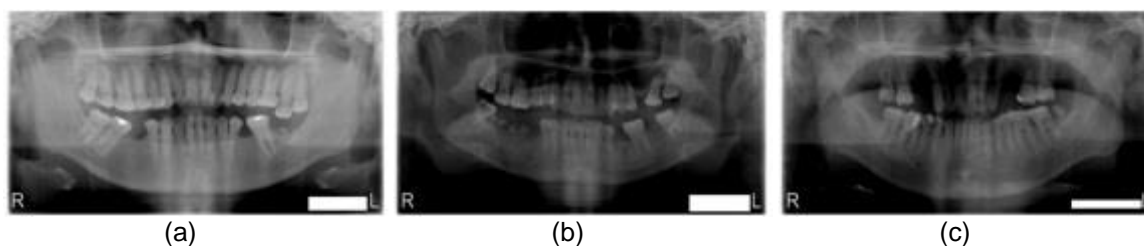


Figure 3. The Image Acquisition of Patient with Proximal Carries (a) Patient 1, (b) Patient 2, (c) Patient 3

3.2. Pre Processing by Cropping

On the the left and right side, as well as in the upper and lower parts of the image of Panoramic Dental X-Ray, there are areas that are not required for subsequent processing. To eliminate these areas in order to facilitate the determination of proximal caries in teeth, we need to crop the image of the teeth. Because the teeth are assembled in one group, then the cropping process required two coordinate points. The first coordinate point determines the upper left position (the position of the patient's right or [R] ight) and the second one determines lower right position of the cropped area (left position patients) [23, 24]. The cropping process results can be seen in Figure 4.

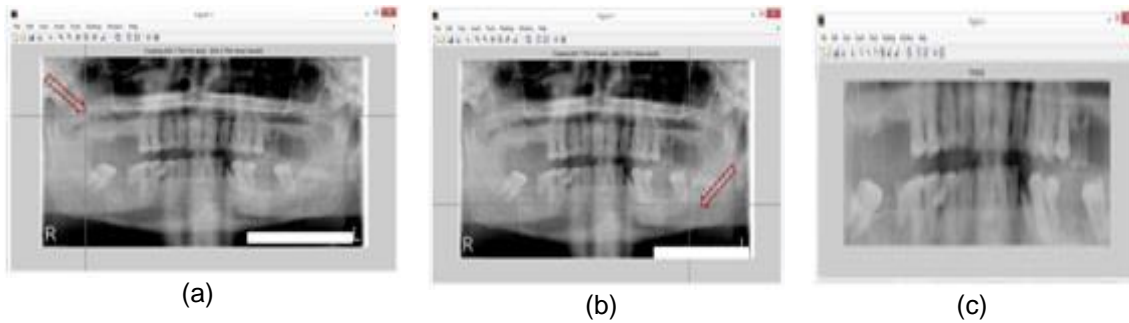


Figure 4. The process of Image Acquisition (a) Initial coordinate point is at upper left (Upper right of the patient position /[R]ight), (b) Initial coordinate point is at lower left (Under right of the patient position/[L]eft), (c) Image Cropping Result

The result of cropping process on input image in Figure 3 can be seen in Figure 5.

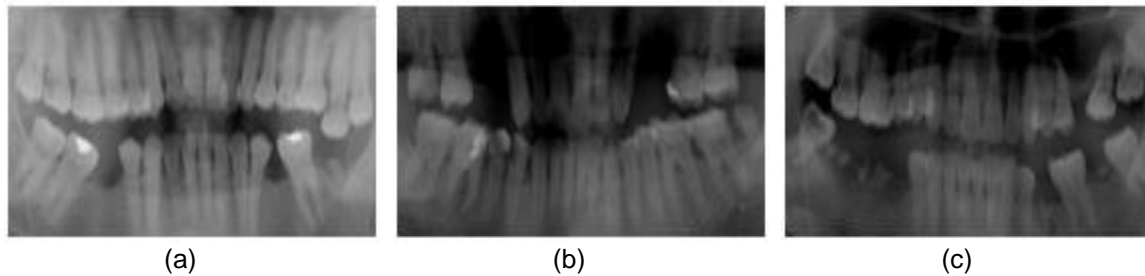


Figure 5. The Cropping Image of Image Acquisition (a) Patient 1, (b) Patient 2, (c) Patient 3

3.3. Morphological Gradient

Morphological Gradient is implied to the cropped image to clarify the edges of each object in the image. It is done by reducing the result of dilation process with that of morphology erosion. Morphology dilation is intended to widen the area of the edges of the object. Meanwhile, the morphology erosion is aimed to discourage or dilute the edge area of the object. There will be differences in the area of each object when they are compared with the objects on the wide dilation results. The stages of the process are illustrated in Figure 6. Processing result of Morphological Gradient process is shown in Figure 7.

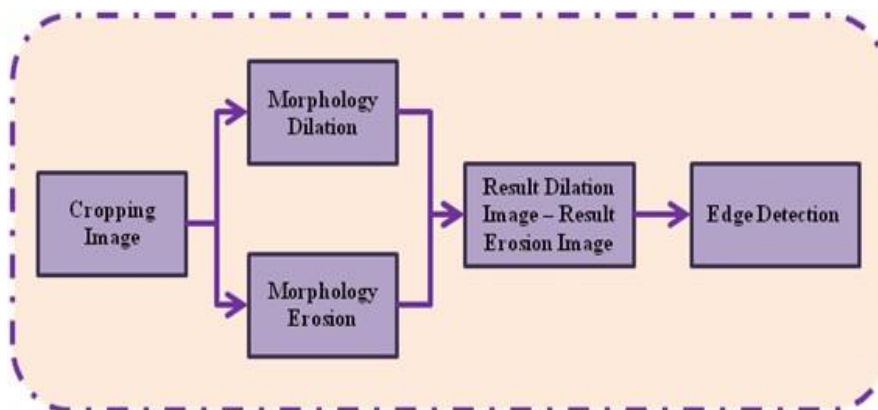


Figure 6. Stages of Morphological Gradient Process




Figure 7. Results of Morphological Gradient against Image Cropping Results(a) Patient 1, (b) Patient 2, (c) Patient 3

3.4. Multiple Morphological Gradient (mMG)

Multiple Morphological Gradient is an iterative process of Morphological Gradient, results in an image with the highest intensity that can be obtained using the Morphological Gradient [25]. mMG will sharpen the boundary edges of objects. The mMG results can be seen in Figure 8.

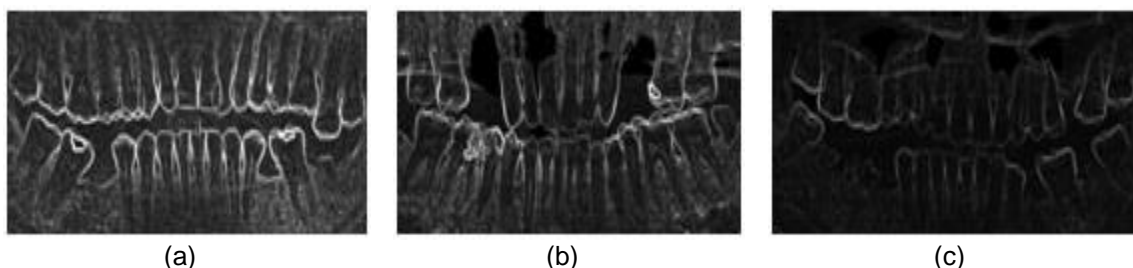


Figure 8. Results of Multiple Morphological Gradient. against image of Morphological Gradient Result (a) Patient 1, (b) Patient 2, (c) Patient 3

3.5. Identification of Proximal Caries in image of mMG result

The image resulted by the mMG has clear edges object so that proximal caries and its severity can visually be better interpreted. Characteristics of proximal caries on the produced image are as follows: (1) Boundary of the side edges of teeth does not overlap. (2) Boundary of the side edges protrude into the teeth (enamel, dentin, or pulp). Figure 9 shows the results of the identification by mMG.

4. Conclusion

This study was conducted to overcome the difficulties in identifying proximal caries through image processing of panoramic dental x-ray image. The image processing method used in this study is Multiple Morphological Gradients. These image processing results can be used to appropriately identify proximal caries and the level of severity.

Based on the results of this study, further research is needed to compare the results of Panoramic Dental X-Ray processed by mMG with the results of bitewing Dental X-Ray from any proximal caries Patients.

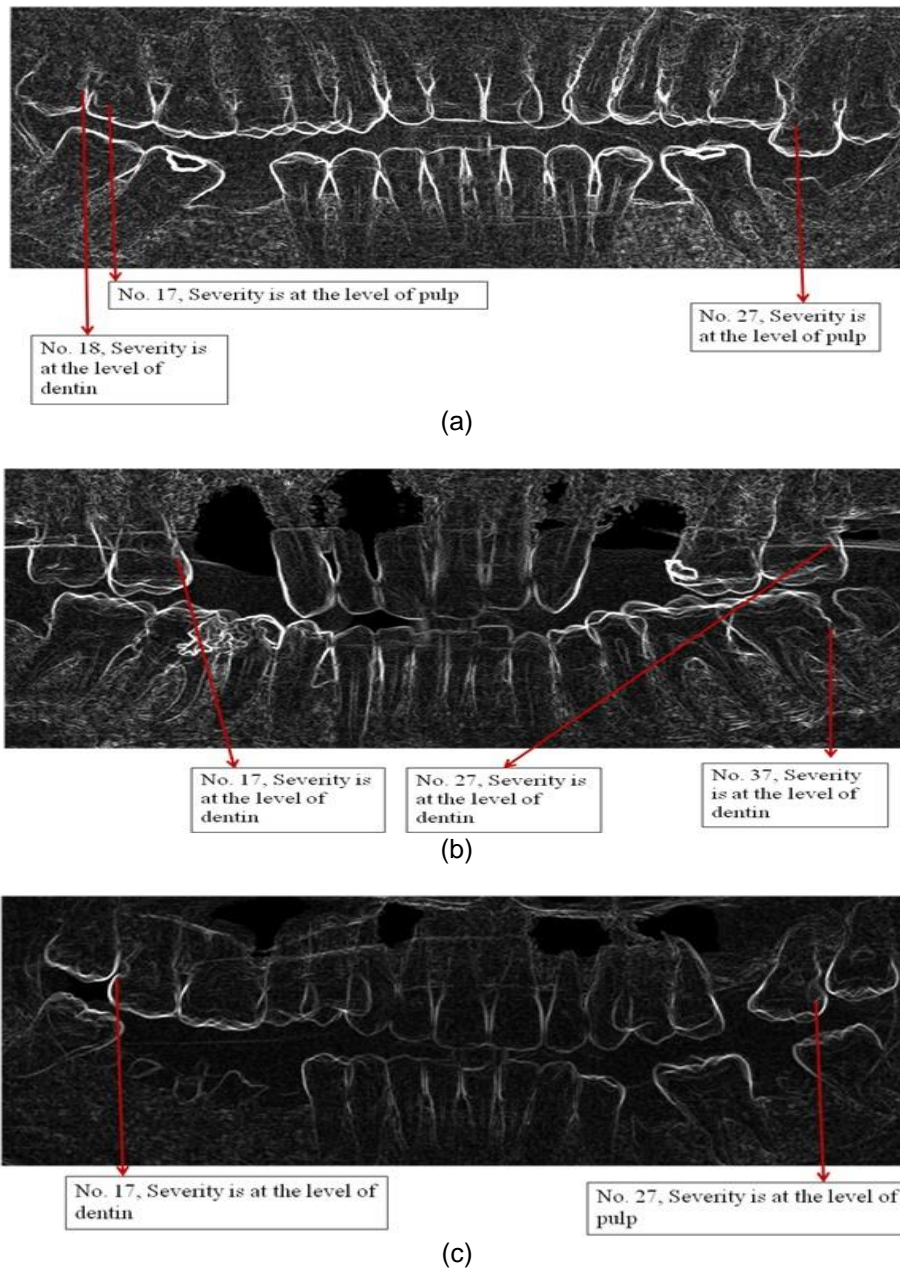


Figure 9. Results of Identification of Proximal Caries (a) Patient 1, (b) Patient 2, (c) Patient 3

5. Acknowledgment

We would like to thank the Head of Department of Radiology, General Hospital of M. Djamil Padang-Indonesia who have allowed us to acquire data from the Department of Radiology, General Hospital of M. Djamil Padang. Furthermore, we would like also to thank the dentists of Semen Padang Hospital who have helped us to analyze the images to be used in this study.

References

- [1] GJ Mount, WR Hume. Preservation and Restoration of Tooth Structure. 2nd Edition. Australia. Knowledge Books and Software. 2005.
- [2] JB Summit, JW Robbins, TJ Hilton, RS Schwartz, JD Santos. Fundamentals of Operative Dentistry: A Contemporary Approach. 3rd edition. Illinois: Quintessence Publishing Co Inc. 2013:31.

- [3] Ramesh T, Upendra G, Sravani Krishna B, Dathar S, Sinha P, MN Raghavendra, Myla S, K Roja. A comparative study to diagnose the accuracy of E-speed film, complimentary metal oxide semiconductor and storage phosphor systems in the detection of proximal caries: An in vitro study. *International Journal of Dental Research*. 2016; 4(1):1-4.
- [4] Merry R Sibarani. Karies: Etiologi, Karakteristik Klinis dan Tatalaksana. *Majalah Kedokteran UKI*. 2014; 30(1):14-22.
- [5] Parveen K, Wyne A. Methods for Caries Detection : An Overview. *Pakistan Oral & Dental Journal*. 2015; 35(4): 666-669.
- [6] Sainu R, Madhumala R, Thouseef, Majeed A, Ravi S, Sayeeganesh N, Jayachandran D. Imaging Techniques in Periodontics: A Review Article. *Journal of Bioscience And Technology*. 2016; 7(2): 739-747.
- [7] Akarслан ZZ, Akdevelioglu M, Gungor K, Erten H, A comparison of the diagnostic accuracy of bitewing, periapical, unfiltered and filtered digital panoramic images for approximal caries detection in posterior teeth. *Dentomaxillofacial Radiol The British Institute of Radiology*. 2008; 37: 458–463.
- [8] Kamburoglu K, Kolsuz E, Murat S, Yüksel S, Ozen T. Proximal caries detection accuracy using intraoral bitewing radiography, extraoral bitewing radiography and panoramic radiography. *Dentomaxillofacial Radiol The British Institute of Radiology*. 2012; 41: 450-459.
- [9] Hoseini Zarch SH, Javadian Langaroodi A, Shafagh Motlagh M. Comparison between Two Digital Panoramic Radiography Techniques for Proximal Caries Detection. *J Dent Mater Tech*. 2013; 2(2): 54-58.
- [10] Abdinian M, Razavi SM, Faghihian R, Samety AA, Faghihian E. Accuracy of Digital Bitewing Radiography versus Different Views of Digital Panoramic Radiography for Detection of Proximal Caries. *Journal of Dentistry*. 2015; 12(4): 290-297.
- [11] Sabarinathan KM, Mahalakshmi B, Shoba S, Vidhya PG, Siva K, Dhanesh Kumar G, Natarajan Vijayarangan. Identification of Tooth Decay in Panoramic X-ray using Image Processing. *Australian Journal of Basic and Applied Sciences*. 2015; 9(6): 60-64.
- [12] Tafakhori Z, Khazaei M, Afshari Poor A. Accuracy of Digital Panoramic Imaging in Detection of Proximal Caries in Posterior Teeth. *Sadra Med Sci J*. 2016; 4(2): 99-106.
- [13] Terry GL, Noujeim M, Langlais RP, Moore WS, Prihoda TJ. A clinical comparison of extraoral panoramic and intraoral radiographic modalities for detecting proximal caries and visualizing open posterior interproximal contacts. *Dentomaxillofacial Radiology*. 2016; 45(4): 20150159.
- [14] Valizadeh S, Rahimian S, Balali M, Azizi Z. Effect of Zooming, Colorization, and Contrast Conversion on Proximal Caries Detection. *Avicenna Journal of Dental Research*. 2016 Jul(inpress).
- [15] Mohtavipour ST, Javadzadeh Haghigat A, Mohtavipour SS, Dehnavi A. Comparison of digital panoramic and bite-wing radiography in proximal caries detection of molar teeth. *J Isfahan Dent Sch*. 2016; 11(6): 531-533.
- [16] Na`am J. Accuracy of Panoramic Dental X-Ray Imaging in Detection of Proximal Caries with Multiple Morphological Gradient (mMG) Method. *International Journal on Informatics Visualization*. 2017; 1(1): 5-11.
- [17] Rad AE, Rahim MS, Norouzi A. Digital Dental X-Ray Image Segmentation and Feature Extraction. *TELKOMNIKA Indonesian Journal of Electrical Engineering*. 2013; 11(6): 3109-3114.
- [18] Sumijan, Madenda S, Harlan J, Wibowo E.P. Hybrids Otsu method, Feature region and Mathematical Morphology for Calculating Volume Hemorrhage Brain on CT-Scan Image and 3D Reconstruction. *TELKOMNIKA Indonesian Journal of Electrical Engineering*. 2017; 15(1): 283-291.
- [19] Madenda S. Pengolahan Citra & Video Digital. Jakarta: Penerbit Erlangga. 2015: 1.
- [20] Na`am J, Harlan J, Madenda S, Wibowo E.P. The Algorithm of Image Edge Detection on Panoramic Dental X-Ray Using Multiple Morphological Gradient (mMG) Method, *International Journal on Advanced Science, Engineering and Information Technology*. 2016; 6(6): 2012-2018.
- [21] Wardoyo S, Pramudyo AS, Rizanti ED, Muttakin I. Exudate and Blood Vessel Feature Extraction in Diabetic Retinopathy Patients using Morphology Operation. *TELKOMNIKA Telecommunication Computing Electronics and Control*. 2016; 14(4).
- [22] Riminarsih E, Karyati CM, Mutiara AB, Wahyudi B, Ernastuti E. MRI Sagittal Image Segmentation from Patients with Abdominal Aortic Aneurysms. *TELKOMNIKA Telecommunication Computing Electronics and Control*. 2016; 14(3): 1105-1112.
- [23] Chen J, Bai G, Liang S, Li Z. Automatic Image Cropping : A Computational Complexity Study. The IEEE Conference on Computer Vision and Pattern Recognition (CVPR). Computer Vision Foundation (CVF) Las Vegas. 2016:507-515.
- [24] Santony J, Na`am J. Infiltrate Object Extraction in X-ray Image by using Math-Morphology Method and Feature Region Analysis. *International Journal on Advanced Science, Engineering and Information Technology*. 2016; 6(2): 239-244.
- [25] Na`am J, Harlan J, Madenda S, Wibowo EP. Identification of the Proximal Caries of Dental X-Ray Image with Multiple Morphology Gradient Method. *International Journal on Advanced Science Engineering and Information Technology*. 2016; 6(3): 344-347.